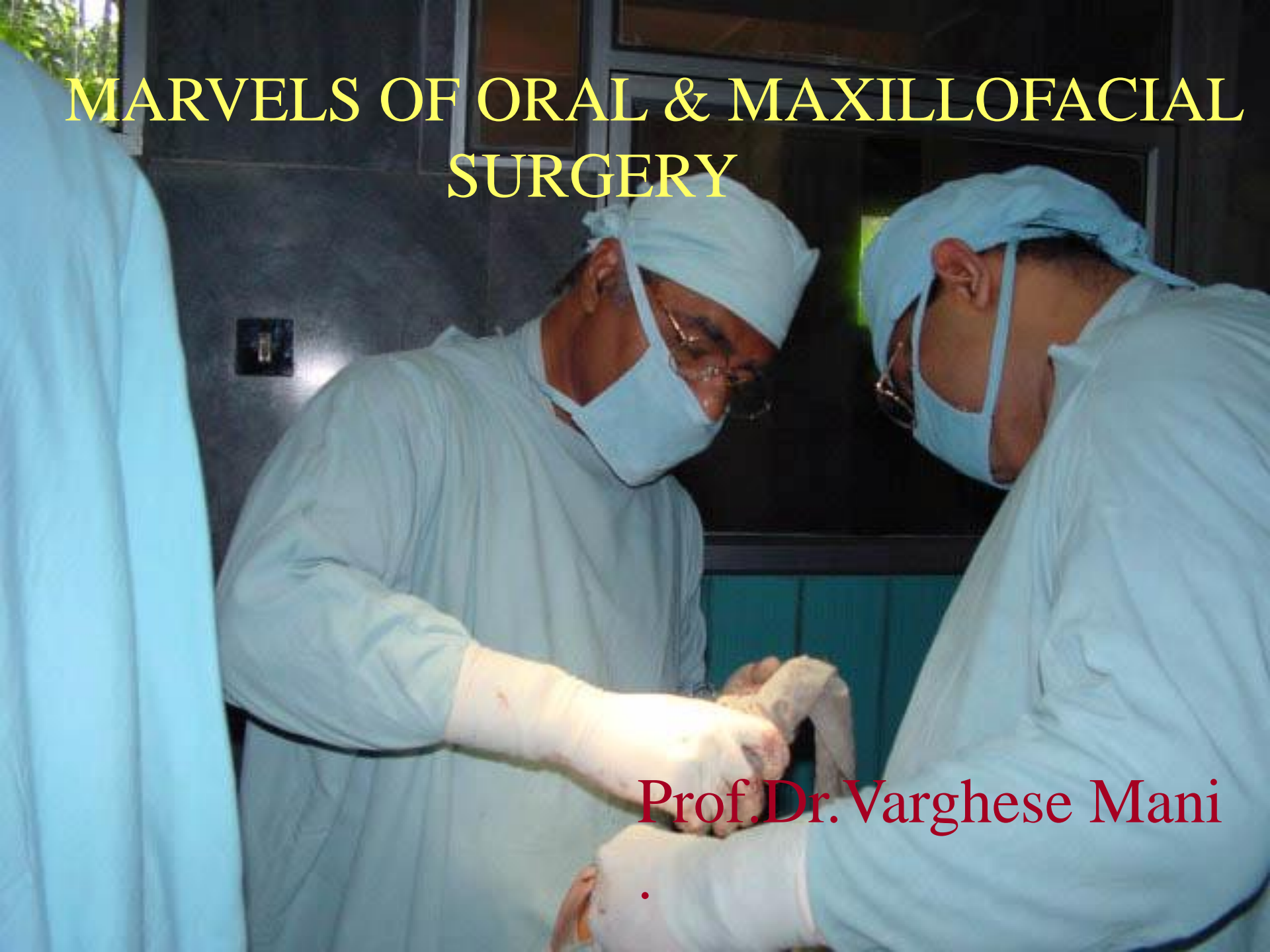

MARVELS OF ORAL & MAXILLOFACIAL SURGERY



Prof. Dr. Varghese Mani

.

- OMFS Bridges Medicine & Dentistry

Humble Beginning

Dento-alveolar Surgery



Oral Surgery



Oral & Maxillofacial Surgery



Craniofacial Surgery



Head & Neck Surgery

Advances in Medicine & Allied Sciences

- Investigations
- Imaging Techniques
- Medications
- Surgical Techniques
- Instrument Technologies
- Biotechnology
- Information Explosion

OMFS too kept the pace

Trauma

IMF,

Trans osseous wiring

Rigid fixation – Plating

Stainless Steel


Titanium

Bioresorbable


Craniofacial Esthetic Surgery



Orthomorphic & Orthofacial Surgery



Orthognathic Surgery



Orthodontic Surgery

Cleft lip & Palate

Facial Clefts

Craniofacial Anomalies

1 Distraction Osteogenesis

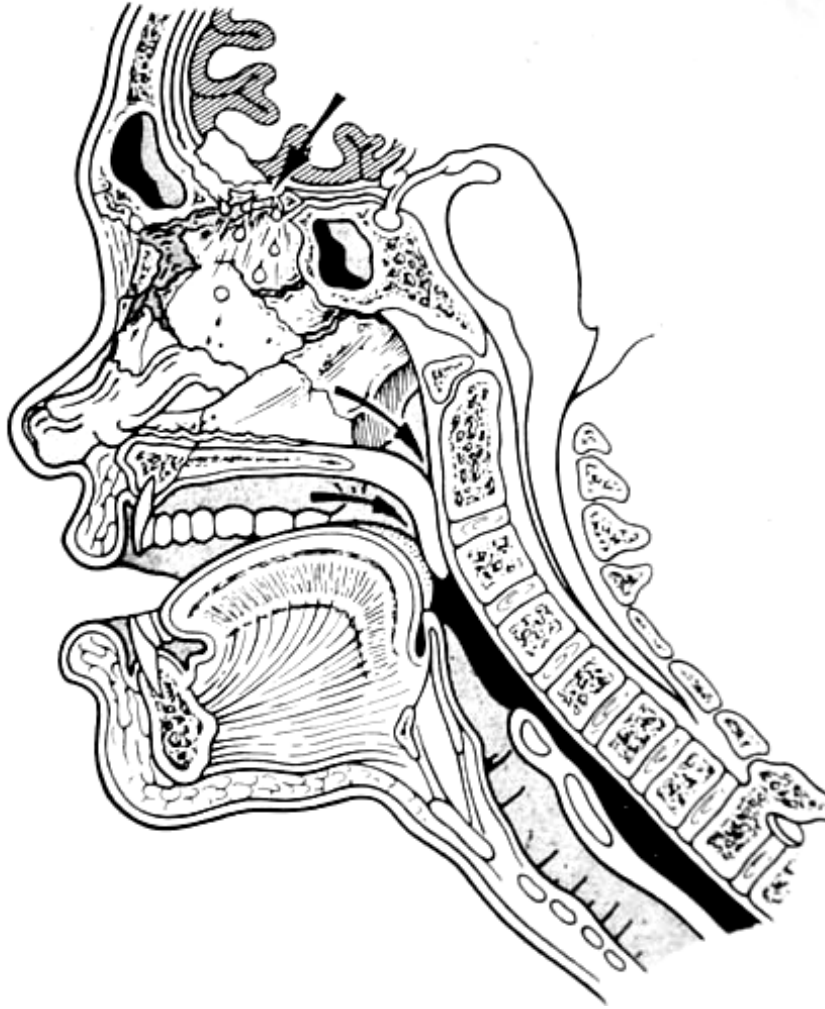
2 Implantology

3 Maxillofacial Oncosurgery

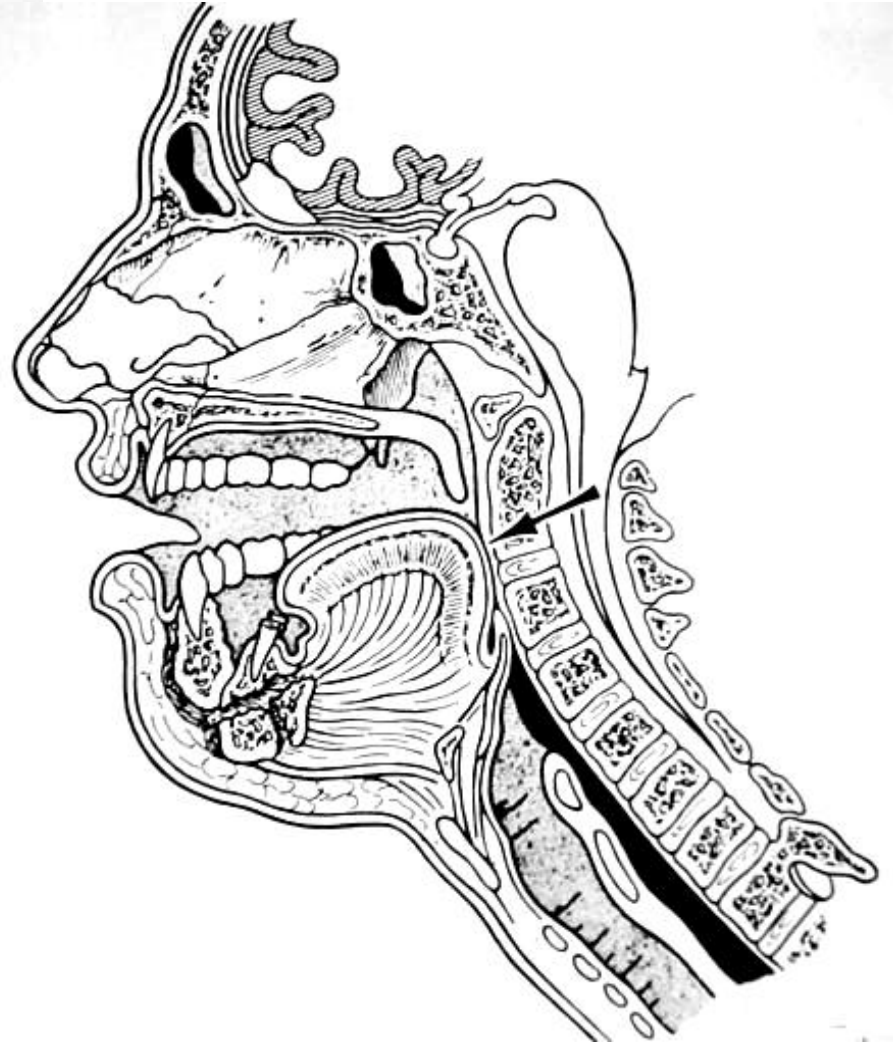4 Microvascular Reconstructive Surgery

TRAUMA

AIRWAY OBSTRUCTION



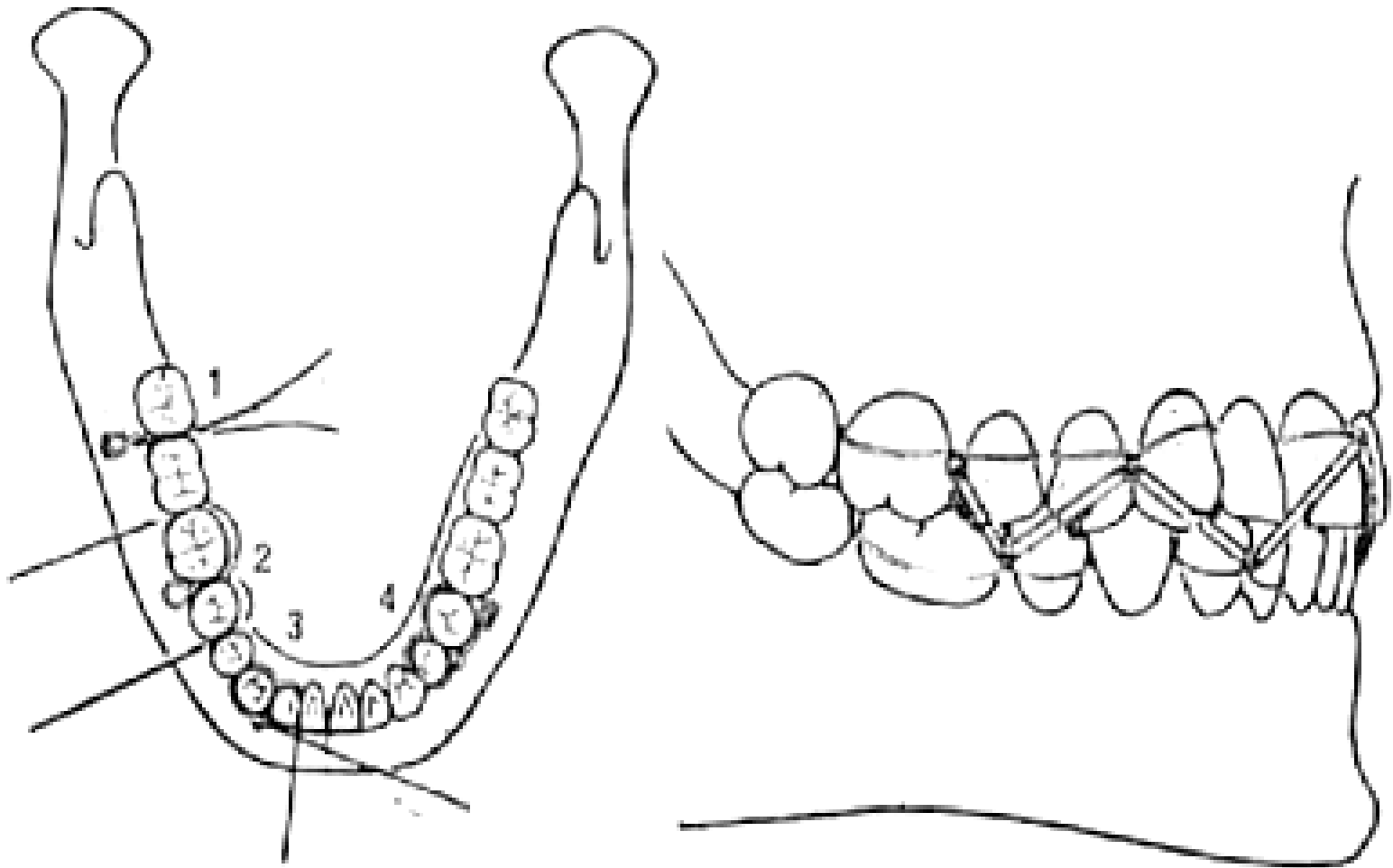
IMP MAX.



FALLEN TONGUE

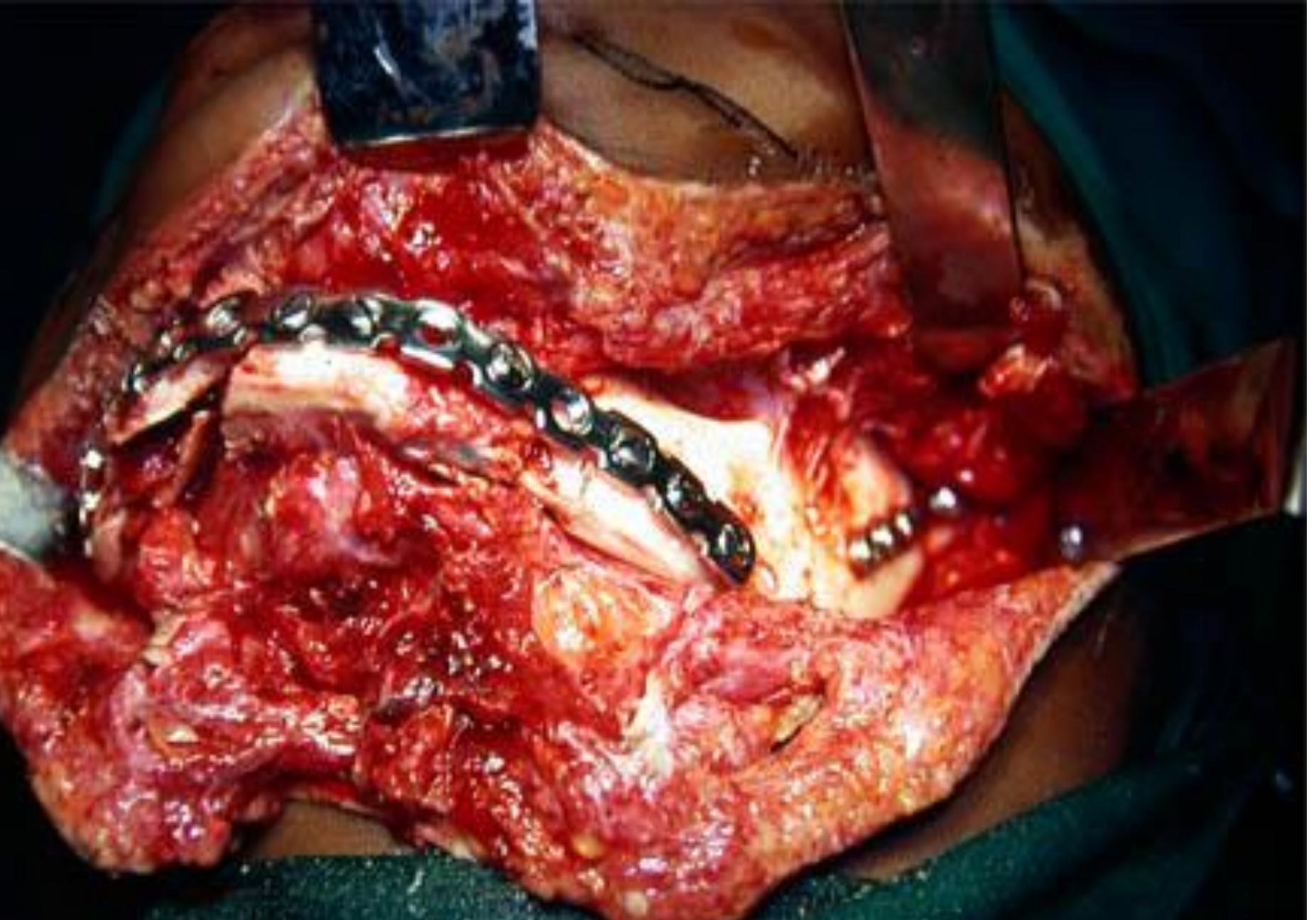
IMF

Intermaxillary Fixation



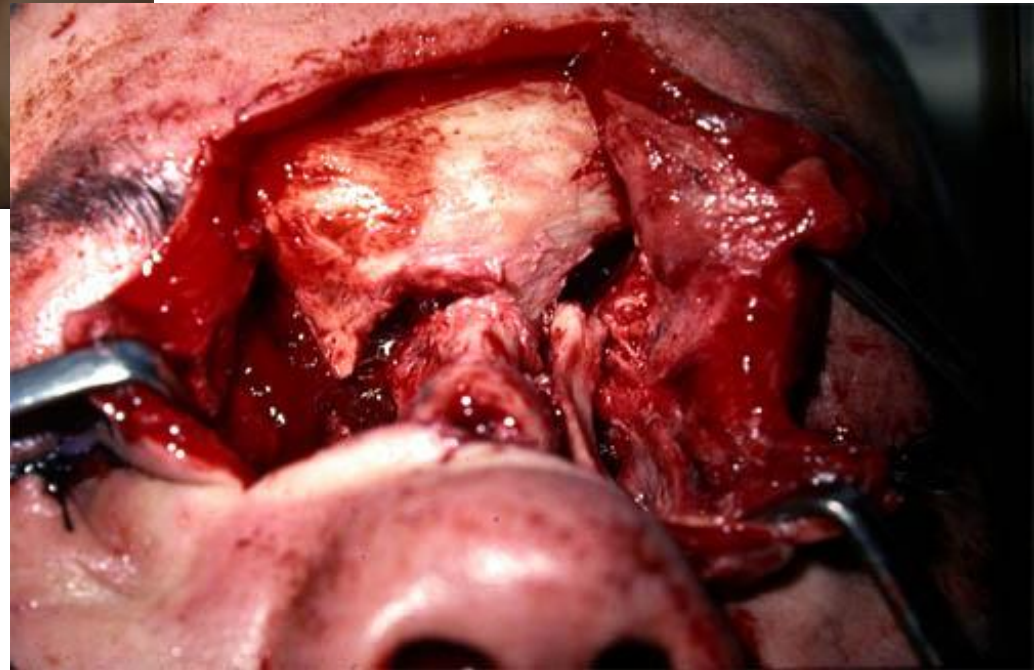
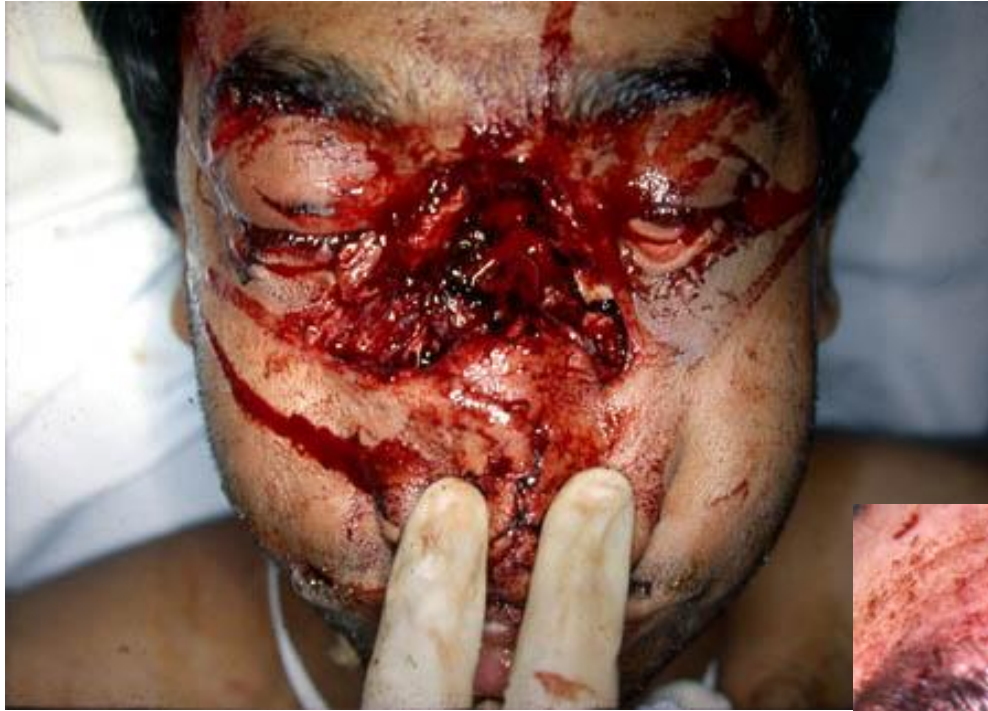PLATING

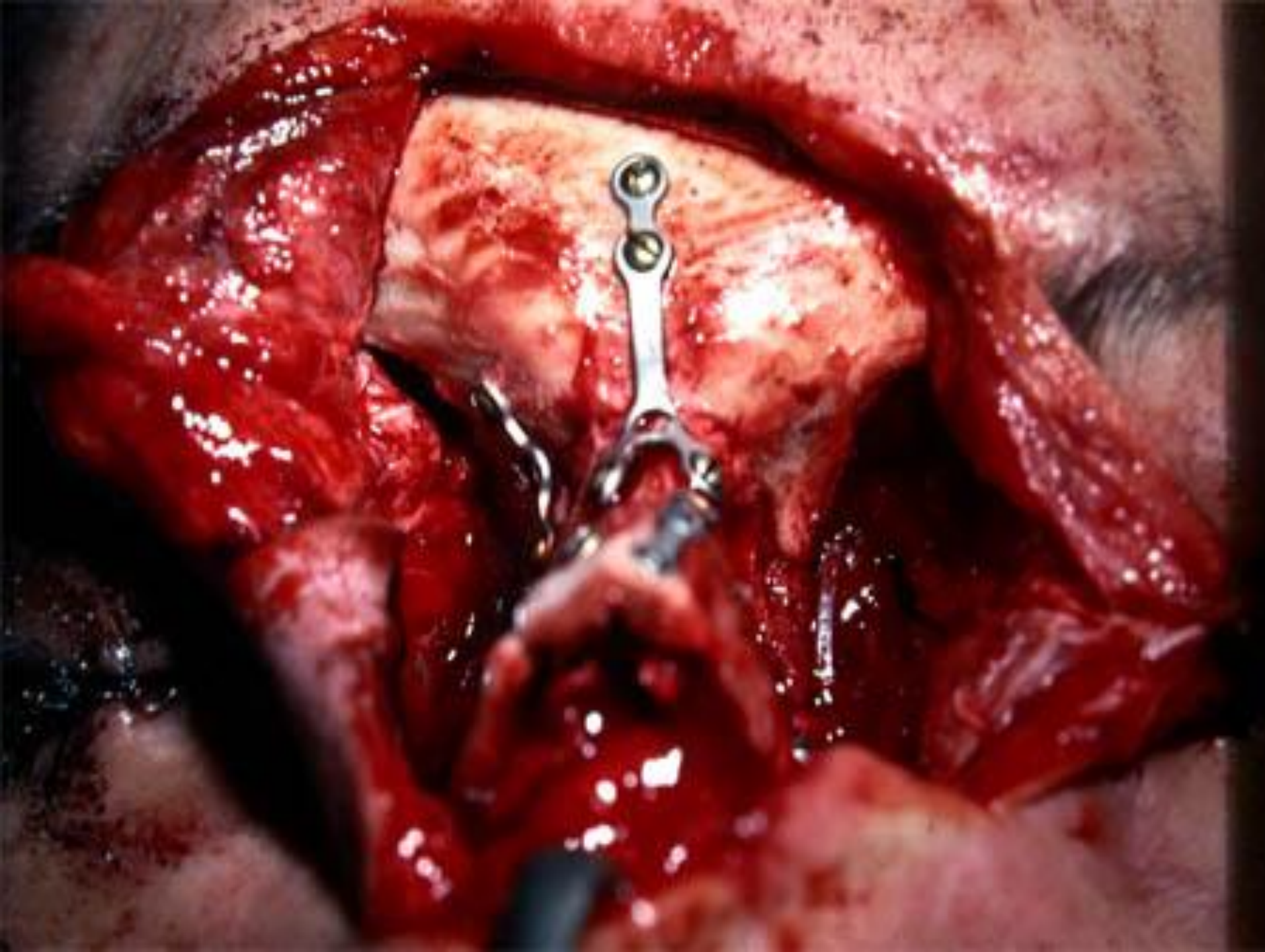




Reconstruction Plate Mandible

Nasoetmoidal Fractures

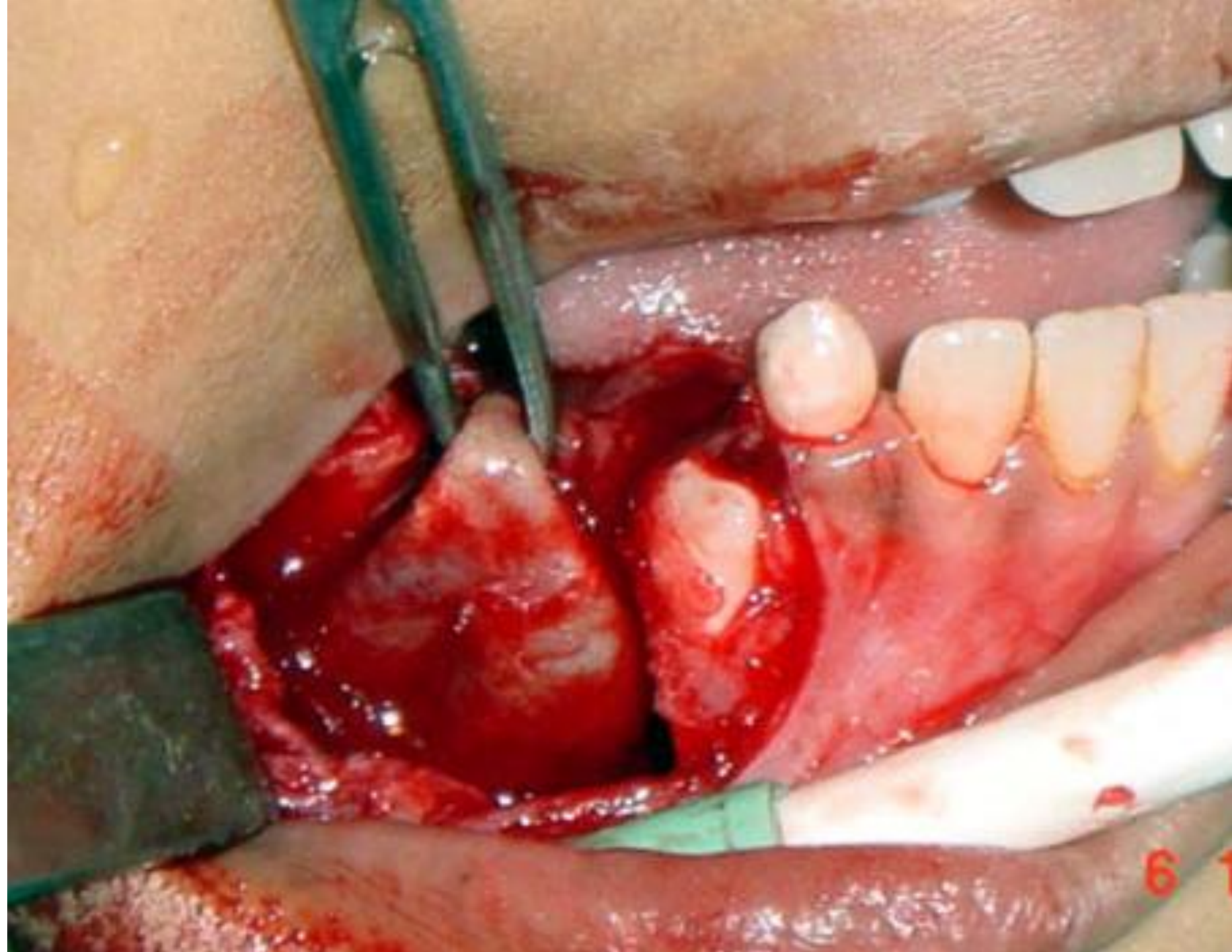


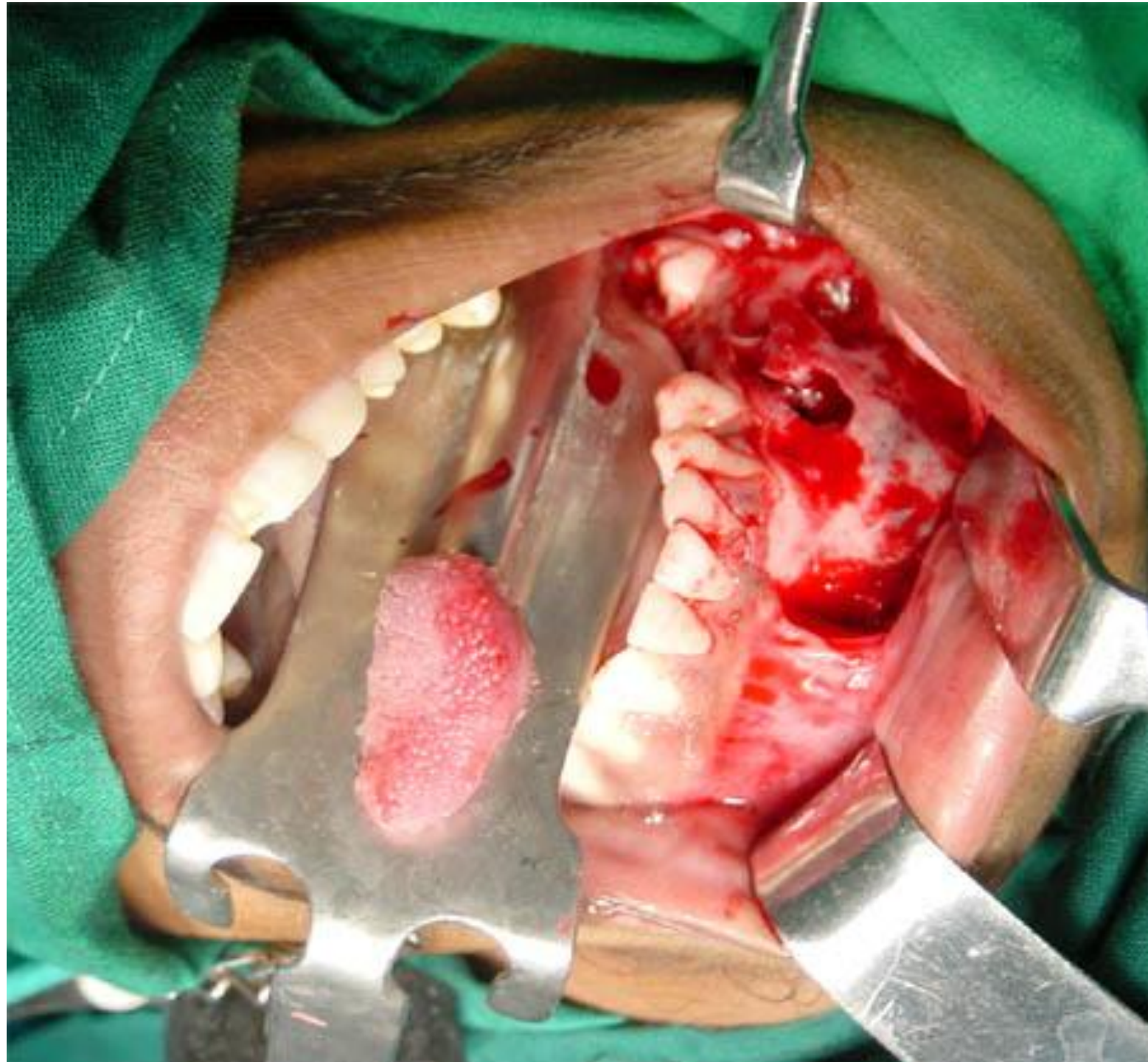

CYST



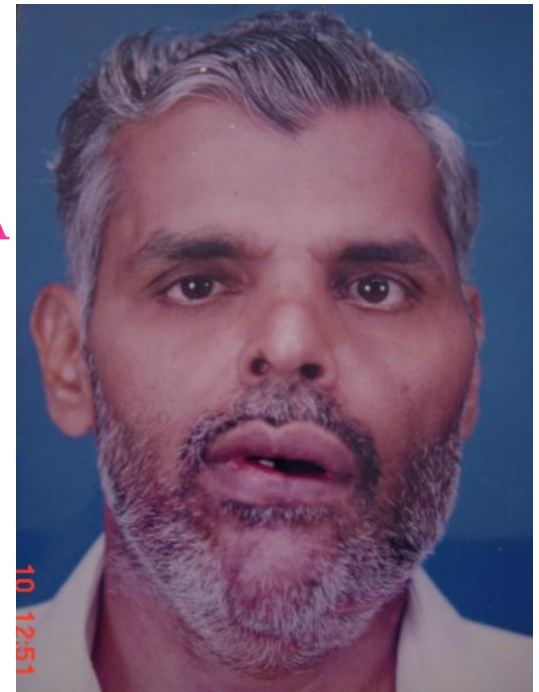
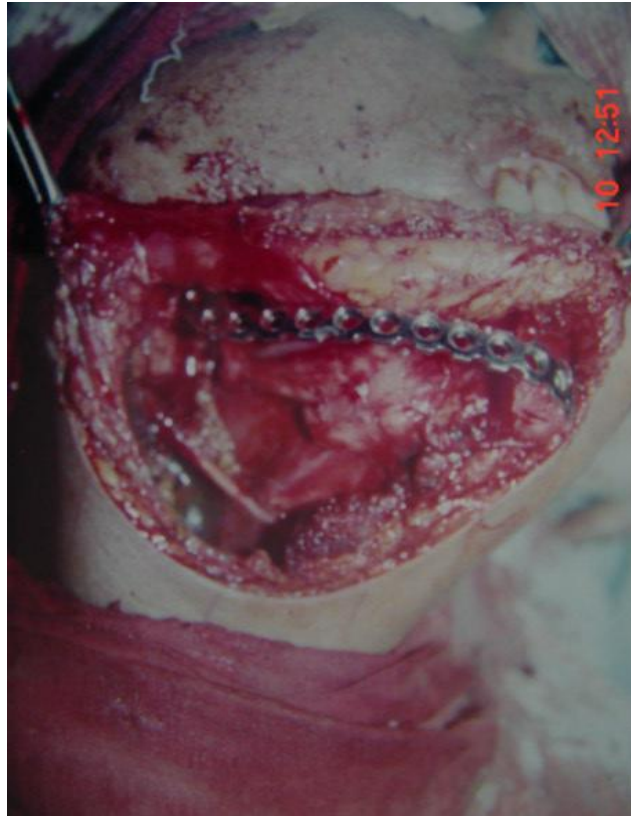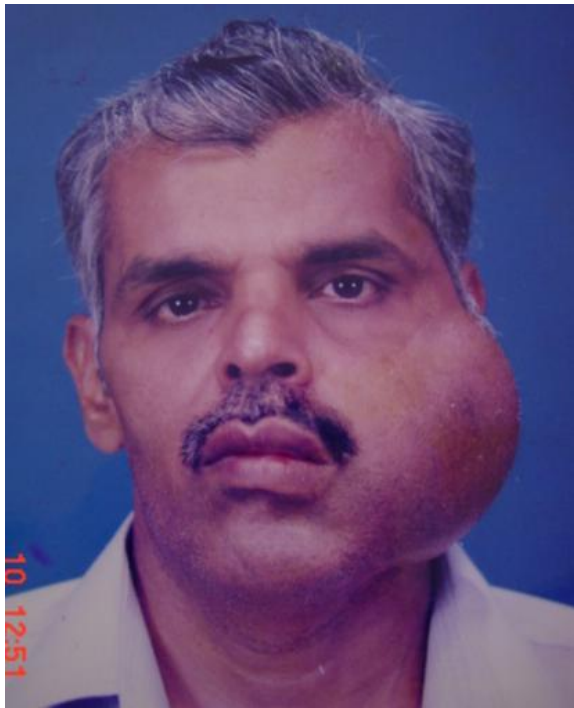
29 8 2002

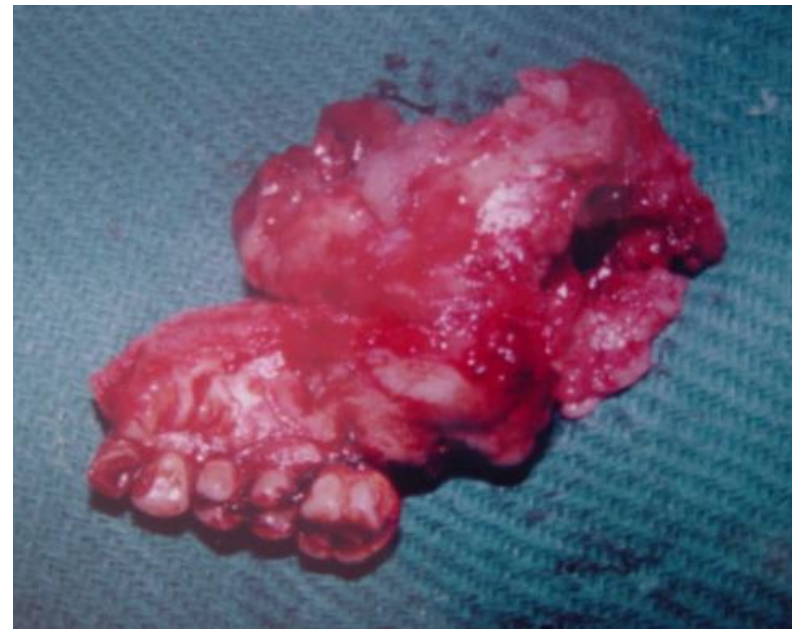
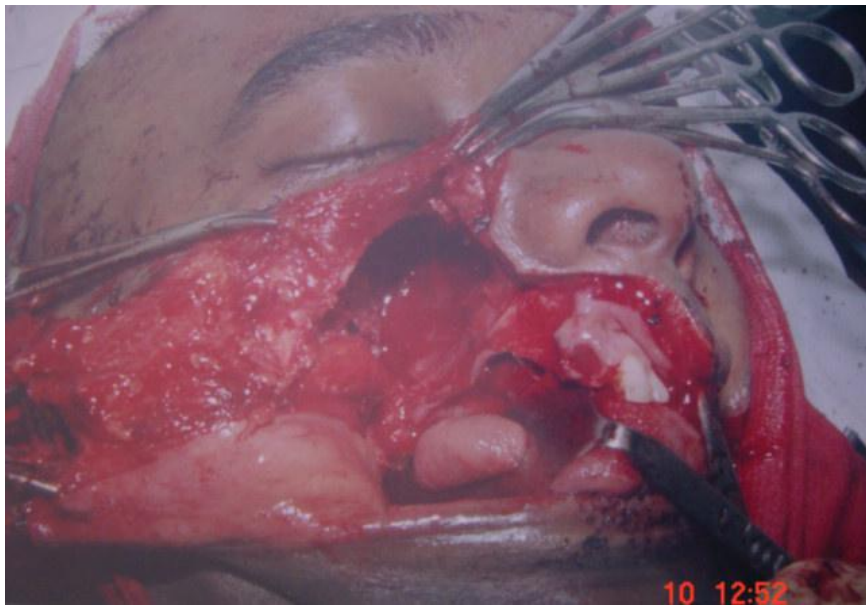


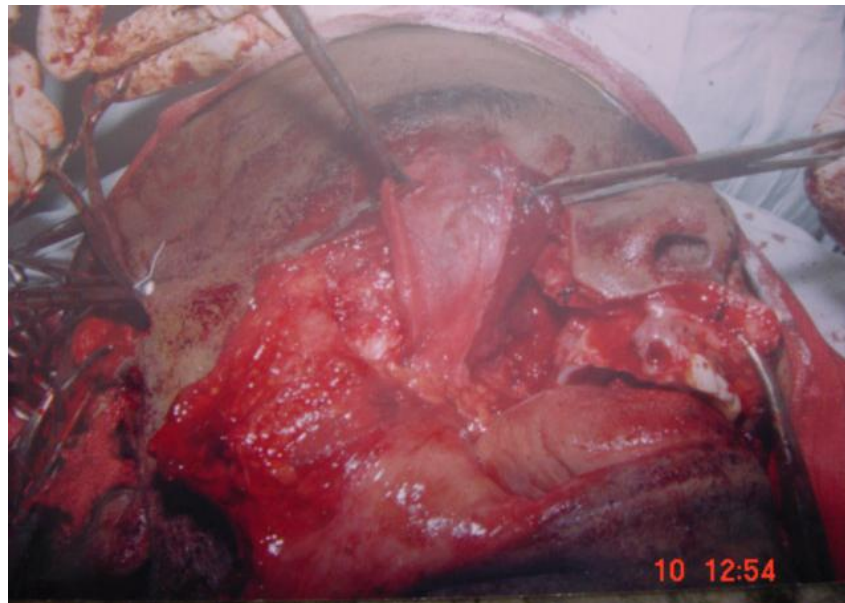
TUMOURS

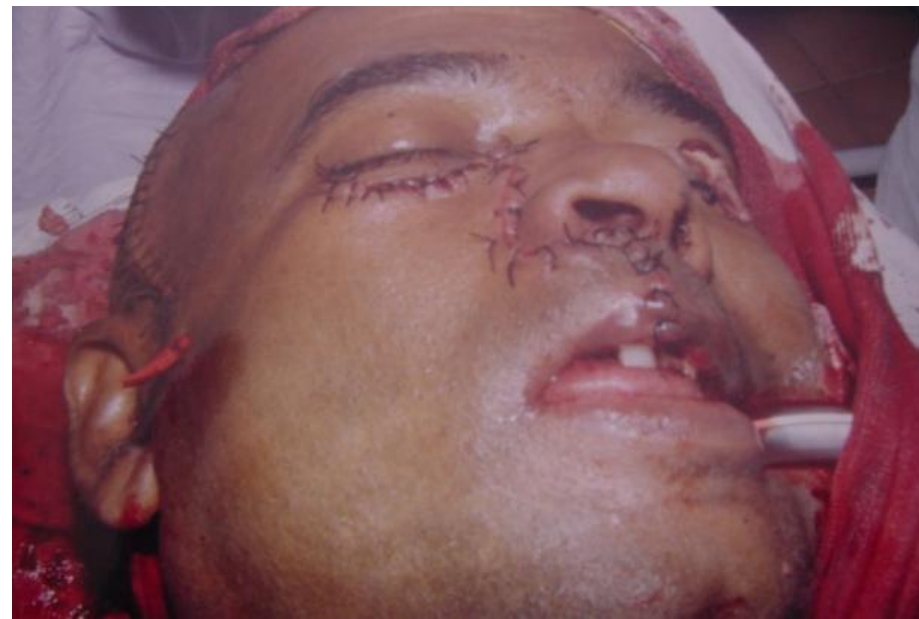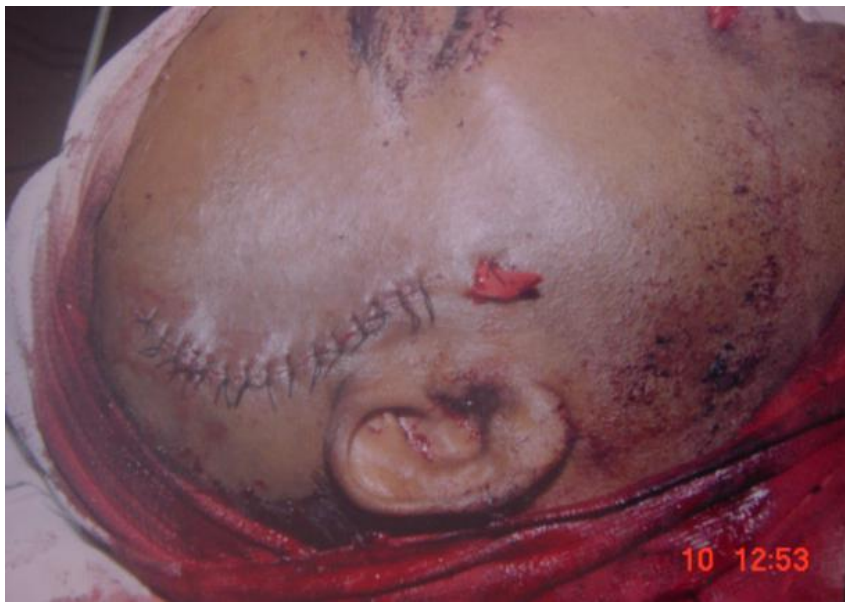AMELOBLASTOMA



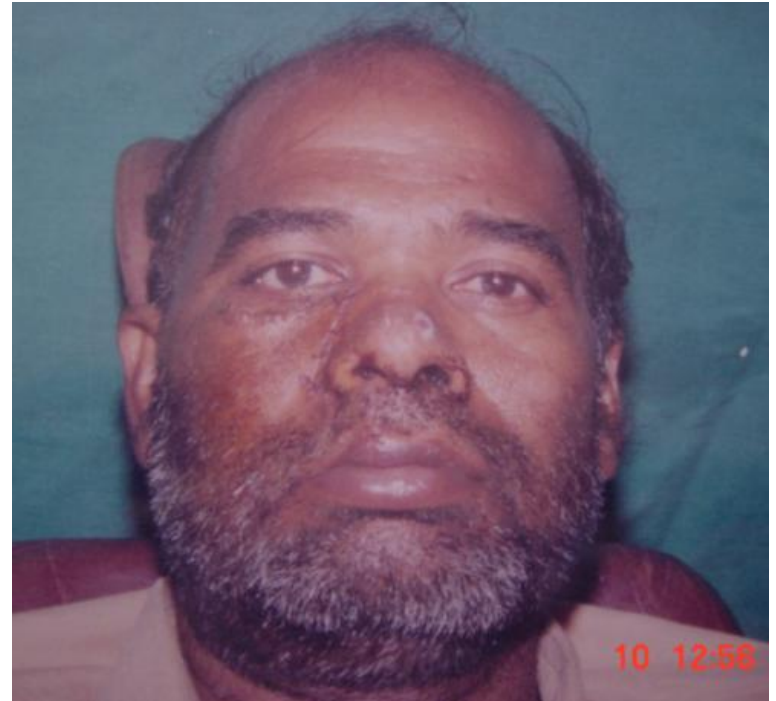
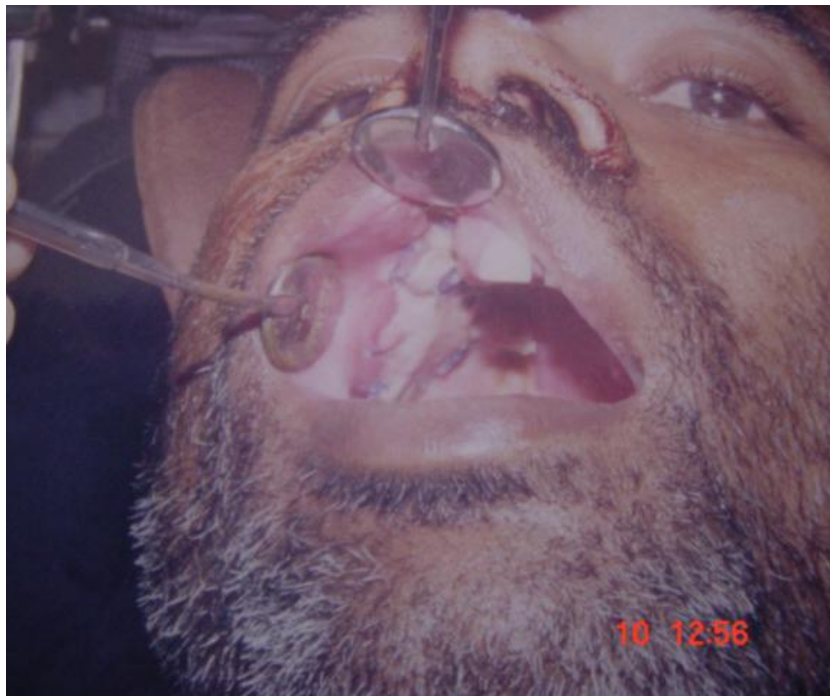
MAXILLARY TUMOR



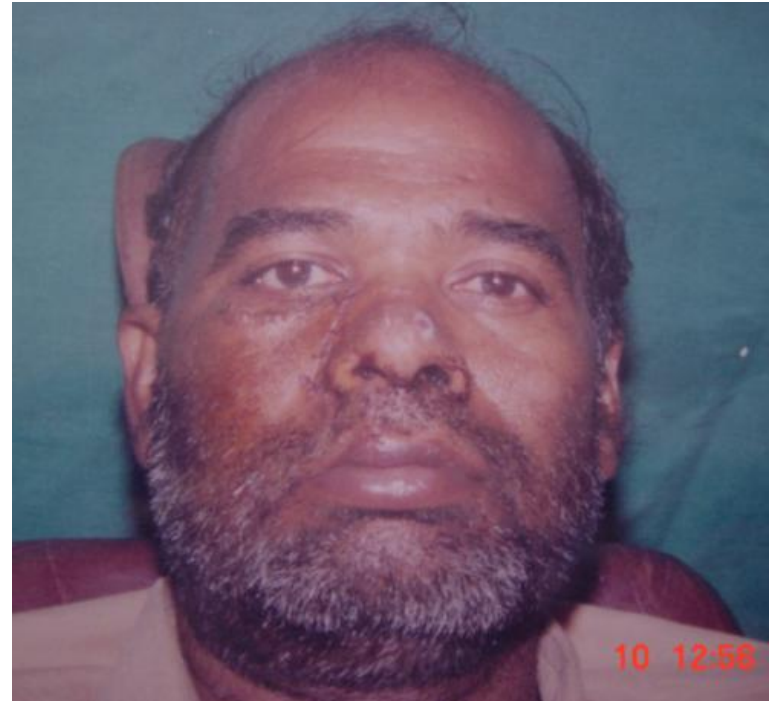

RECONSTRUCTED WITH TMF FLAP






RECONSTRUCTED WITH TMF FLAP





FACIAL PROPORTION



Beauty is no more skin-deep


Deft carpentry on bone



Move the segments in all three dimensions of space



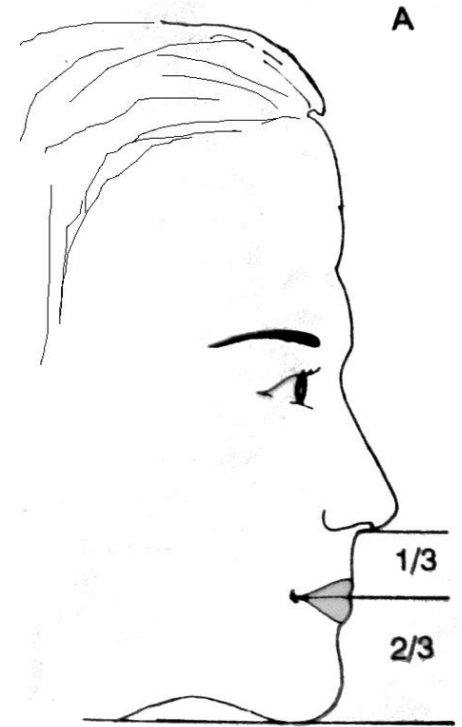
Alter the shape & size



Towards better esthetics & function.

Painted face or a sculptured face ?

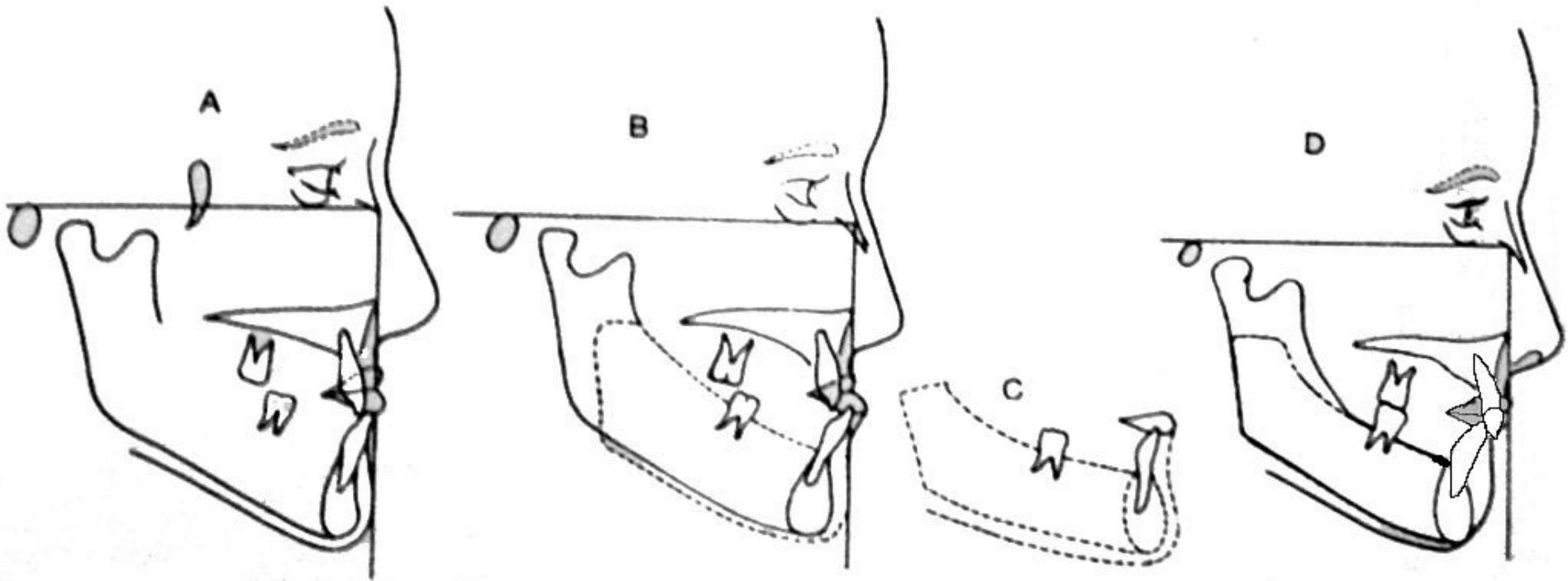
Analysis of beauty



Is proportions simple notions ?



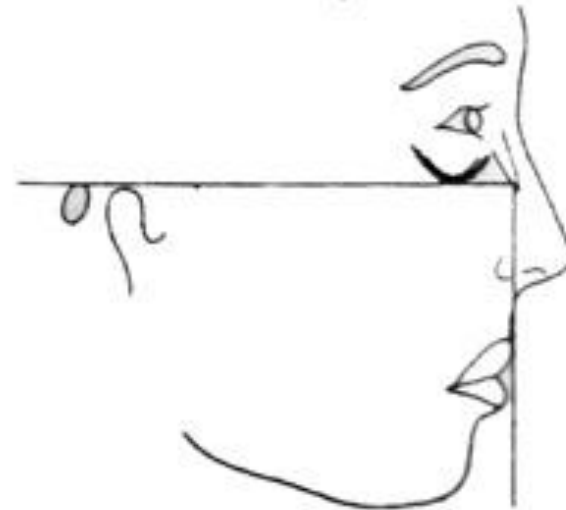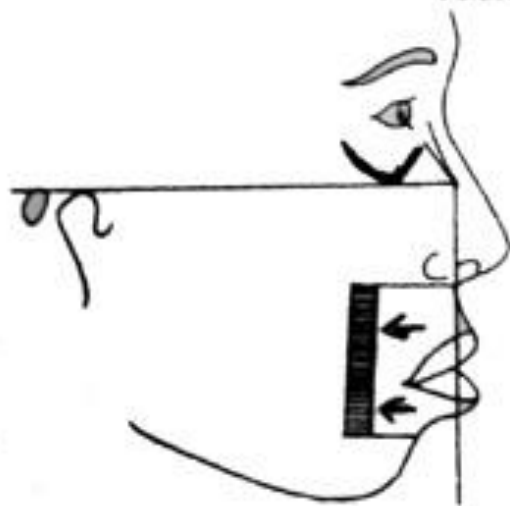
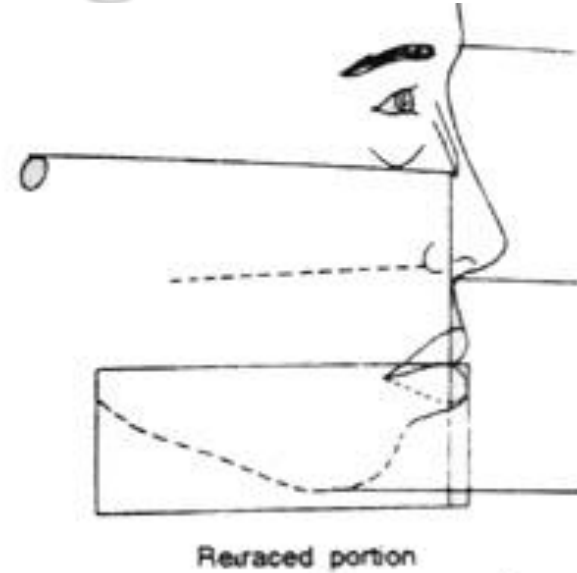
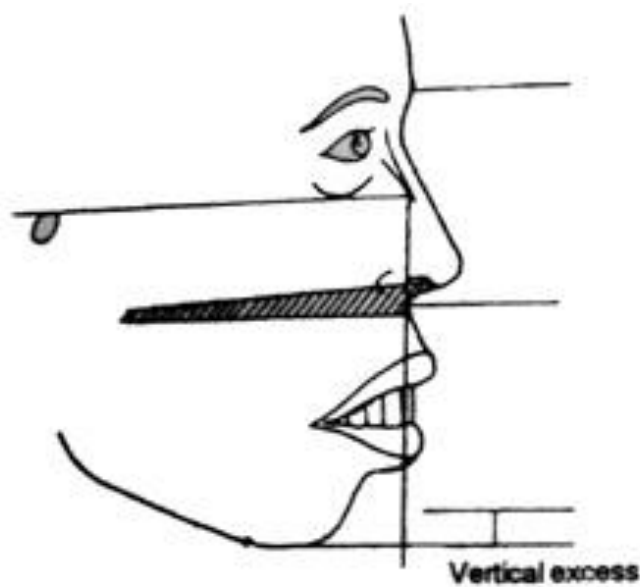
Prediction tracing - mandible



Go wrong and face the music.



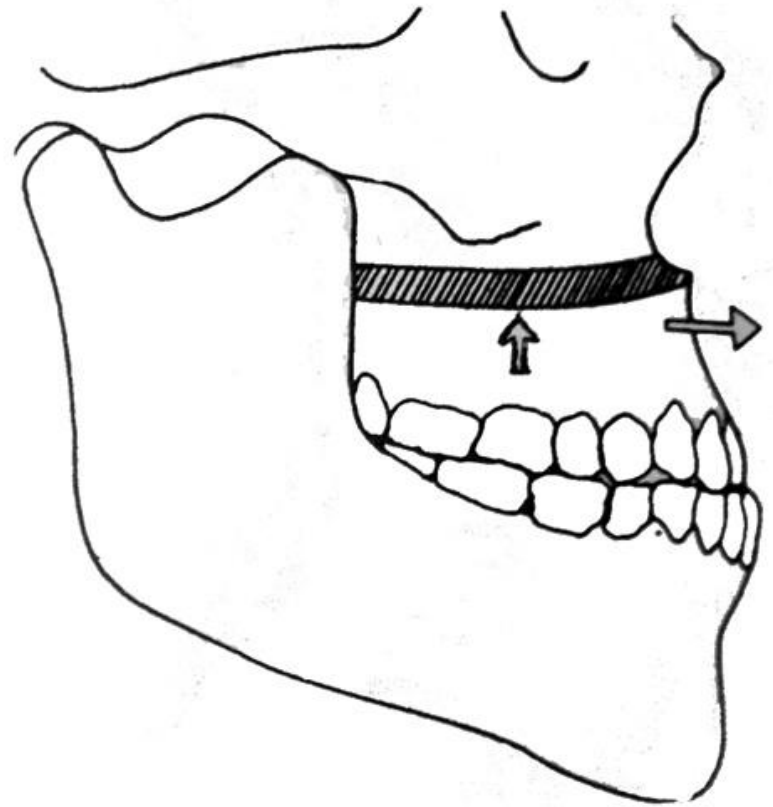
Prediction tracing - maxilla

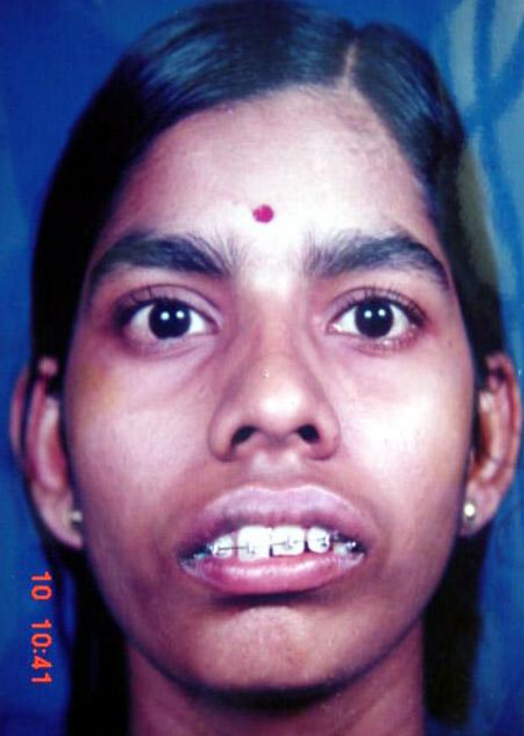

Over enthusiasm predicts doom.

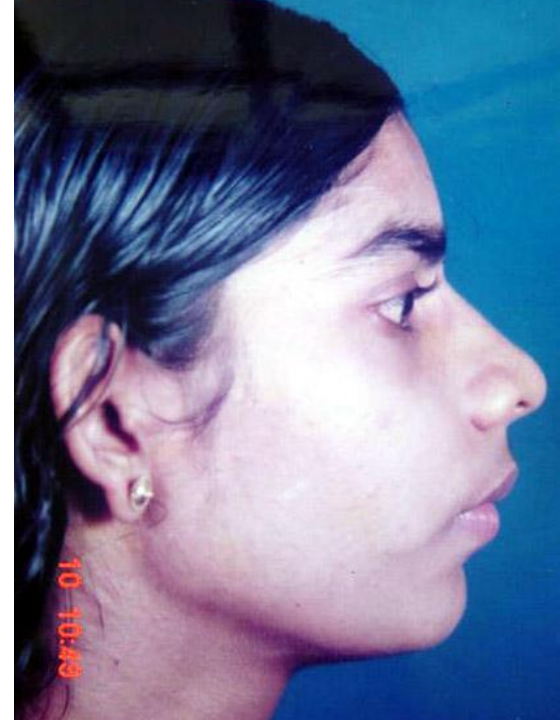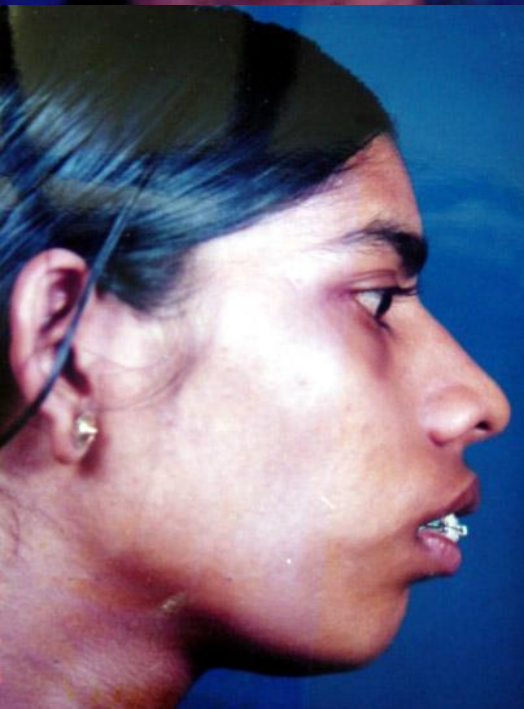Lefort I Osteotomy

- **Vertical and sagittal excess of maxilla - Protruded upper jaw, gummy smile.**
- **Facial asymmetry – Occlusal cant.**
- **Retruded maxilla – Hypo plastic maxilla, Cleft lip & palate deformities.**

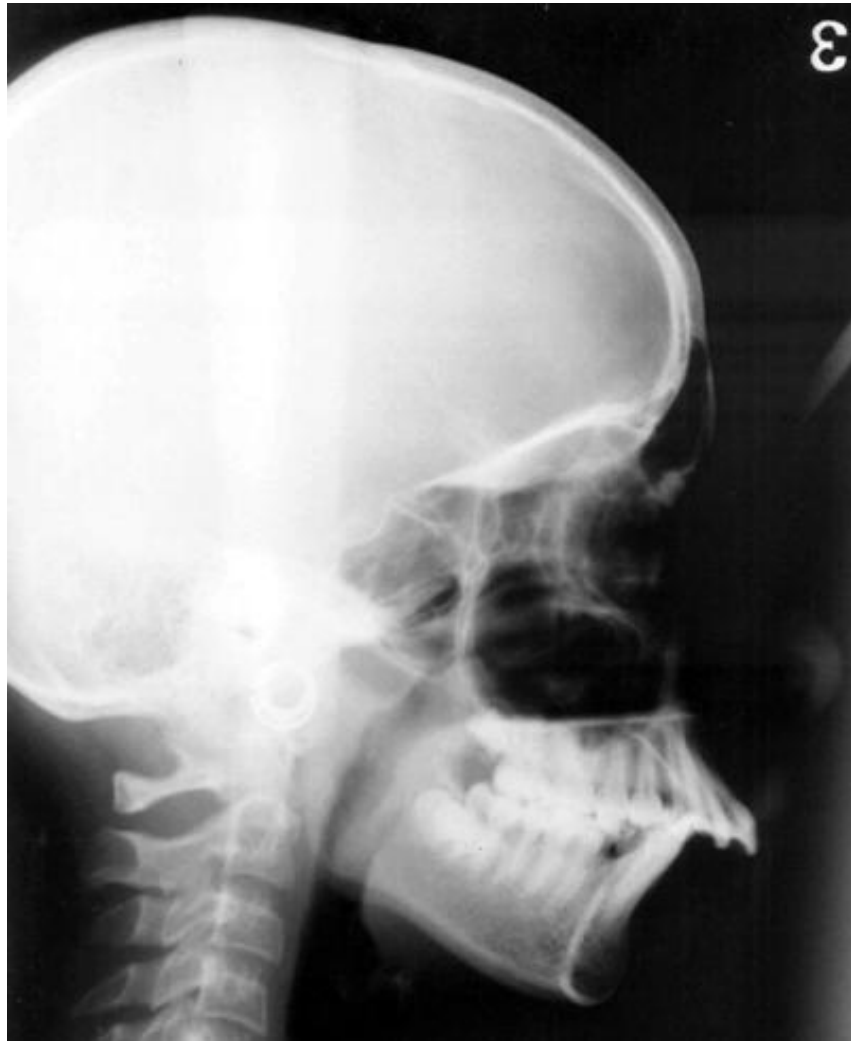



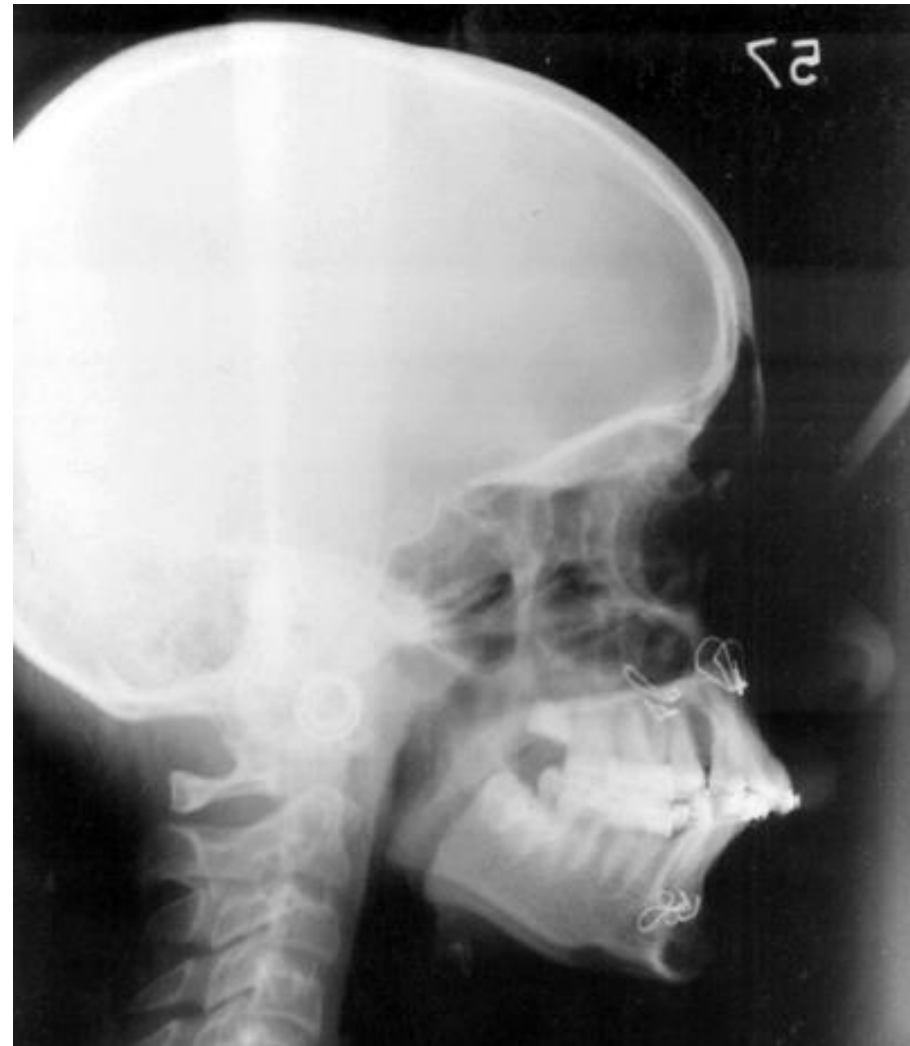LFI & AMO



Pre – op x-ray




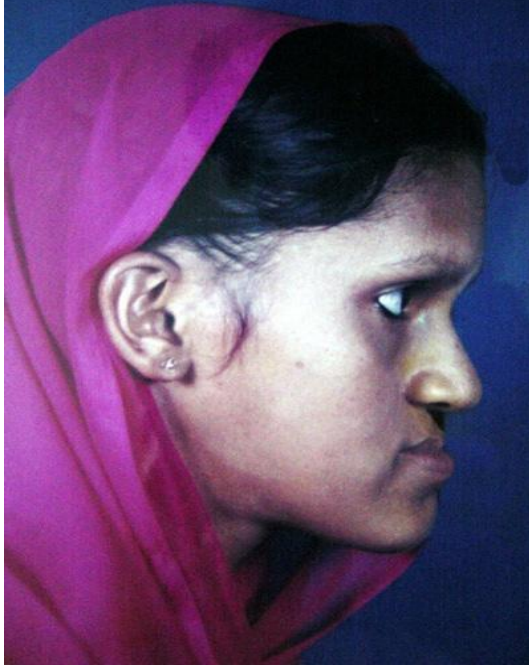
Post – op x-ray



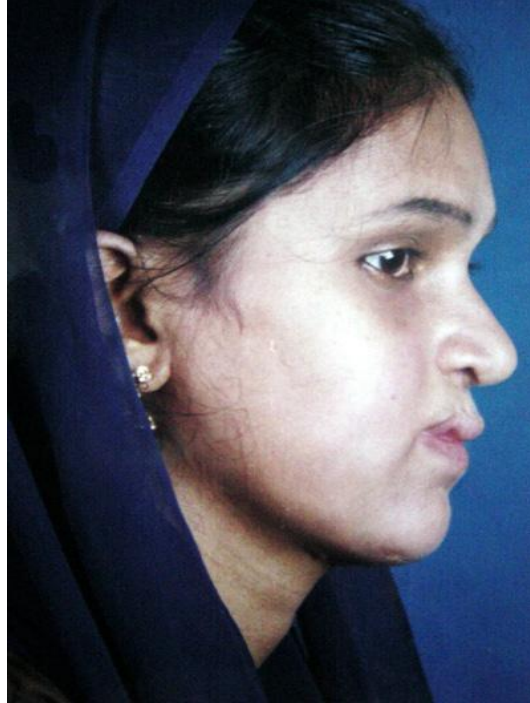Who is afraid of Gummy Smile?



Pre-
i
pop



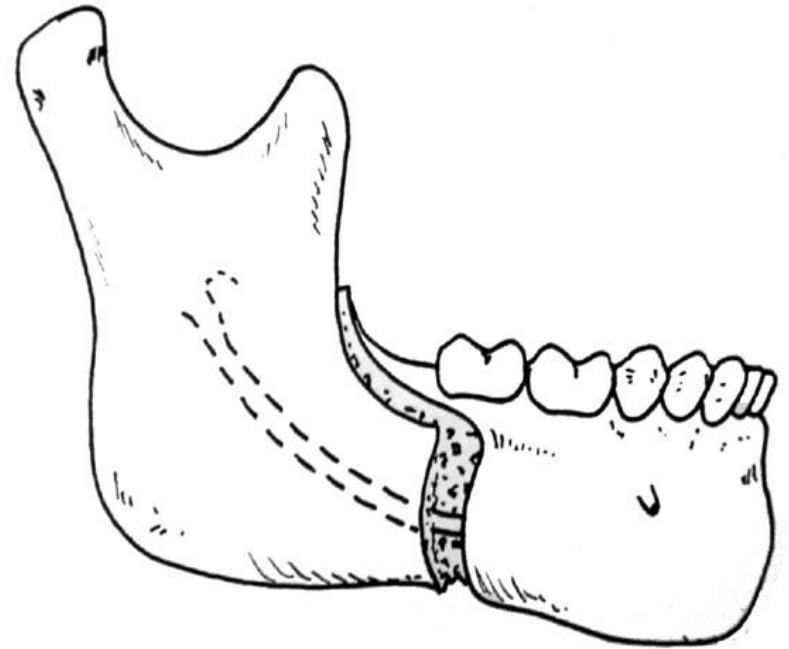
30-4030392A-4r0#0F



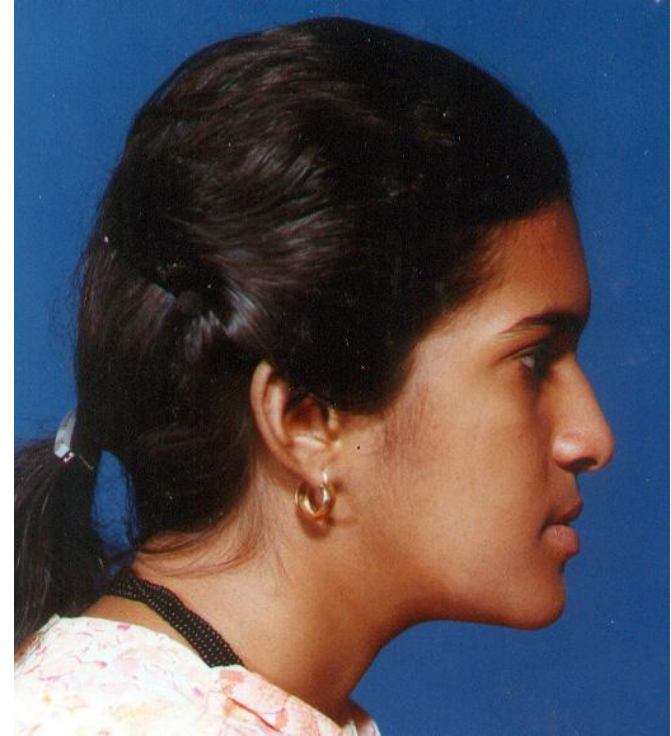
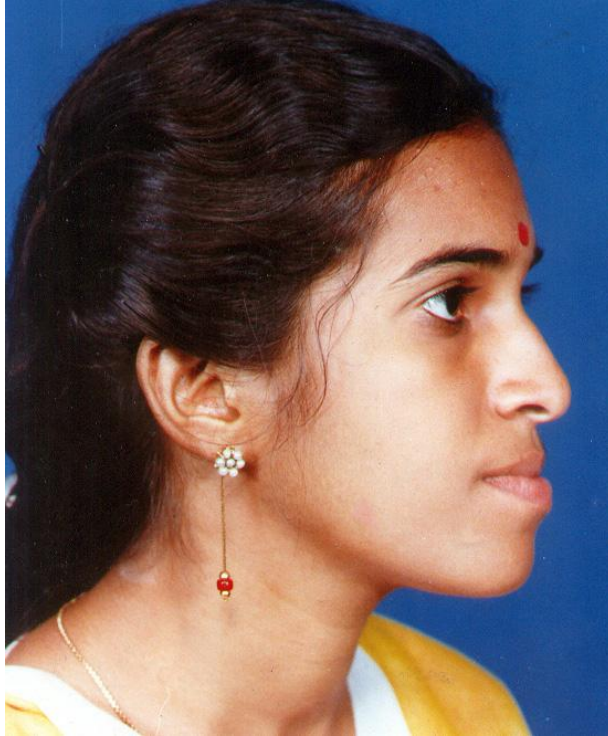Post-
i
pop

Sagittal Split Osteotomy

Versatile procedure
for both mandibular
prognathism and
retrognathism.



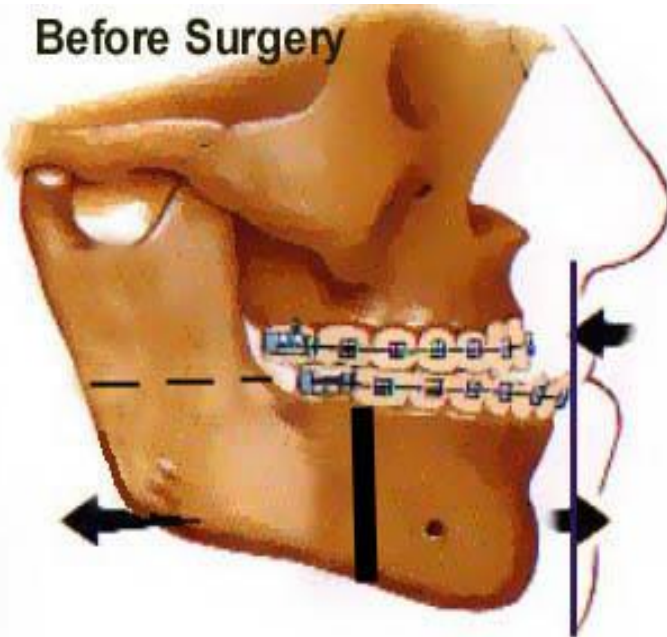
P
r
e



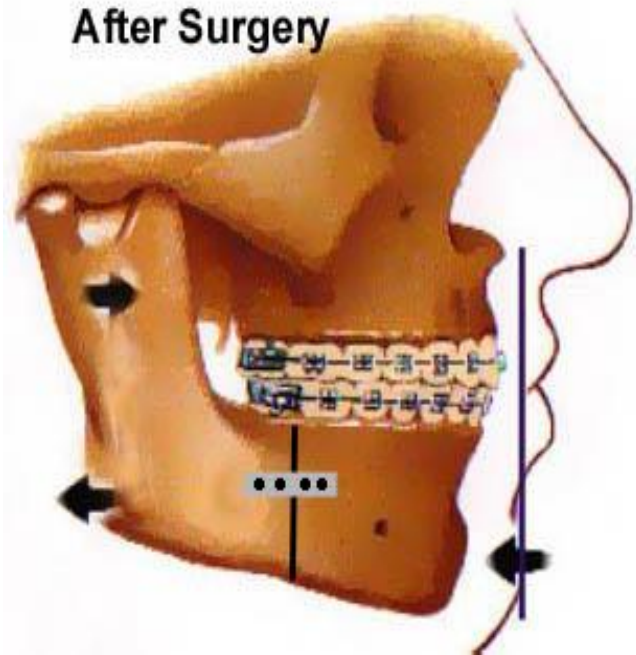
P
o
s
t

—

Before Surgery



After Surgery

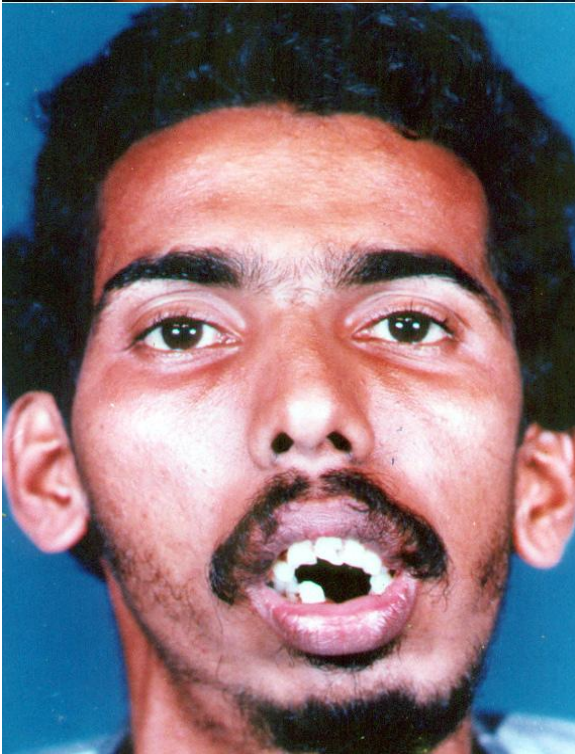
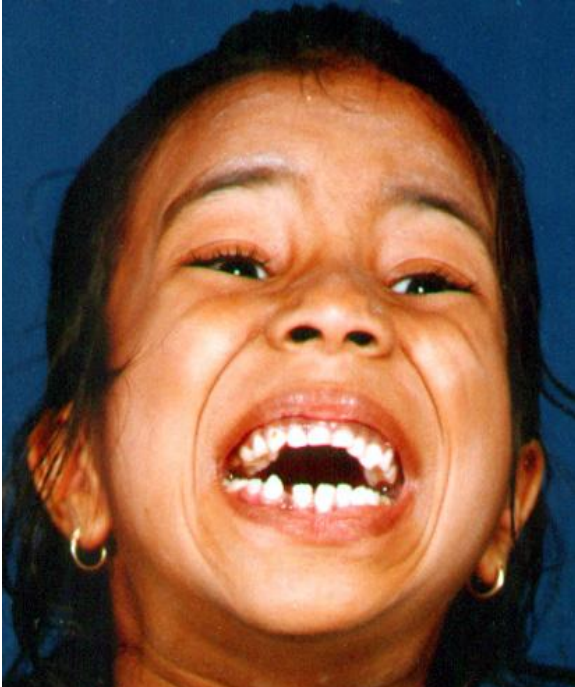
—

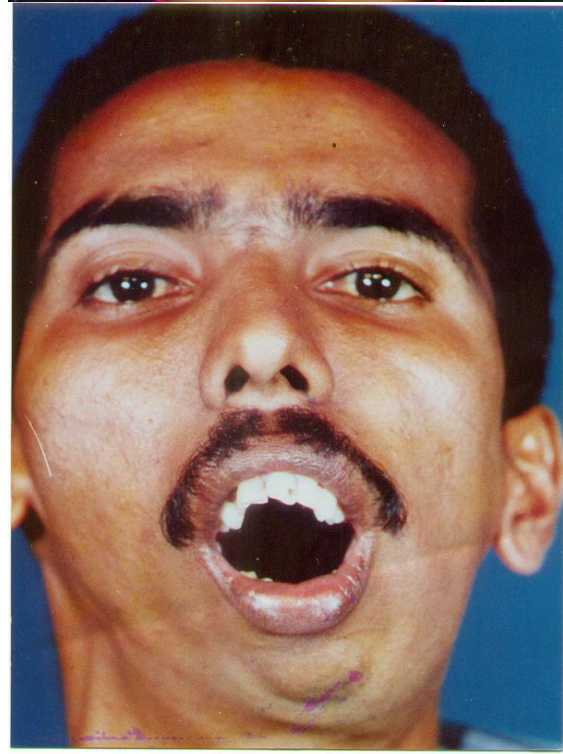
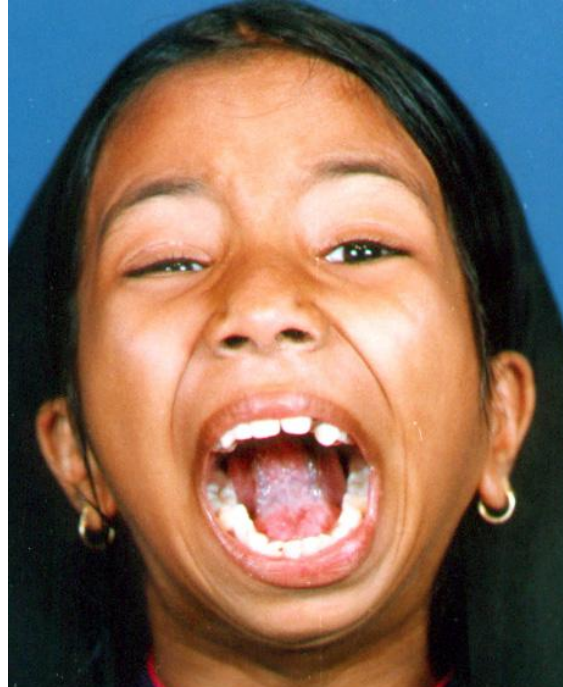o
p

o
p

P
r
e
-
p



A
n
k
y
-
o
-
s
-
s




P
o
s
t
-
o
p

P
r
e
-
o
p



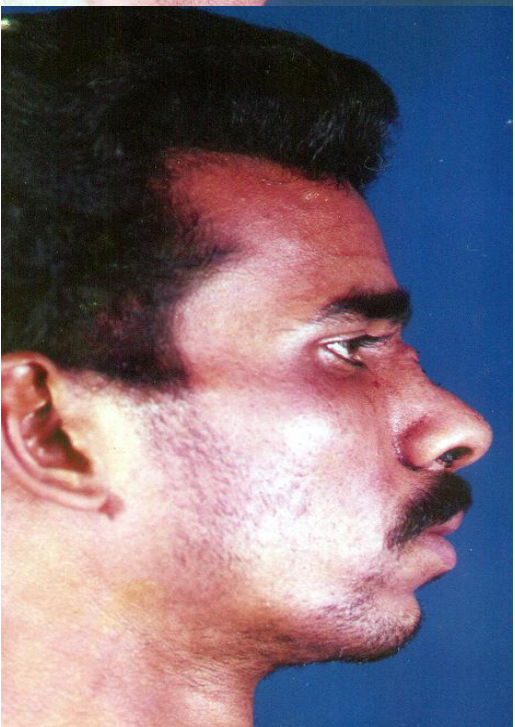
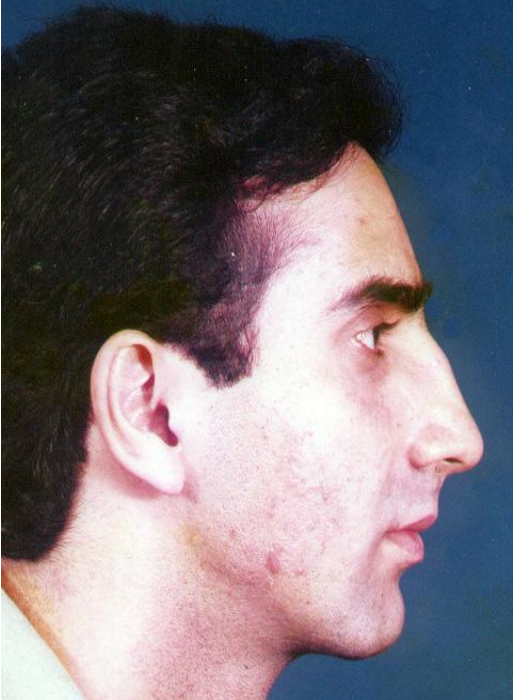
F
a
c
i
a
l

A
s
y
m
m
e
t
r
y

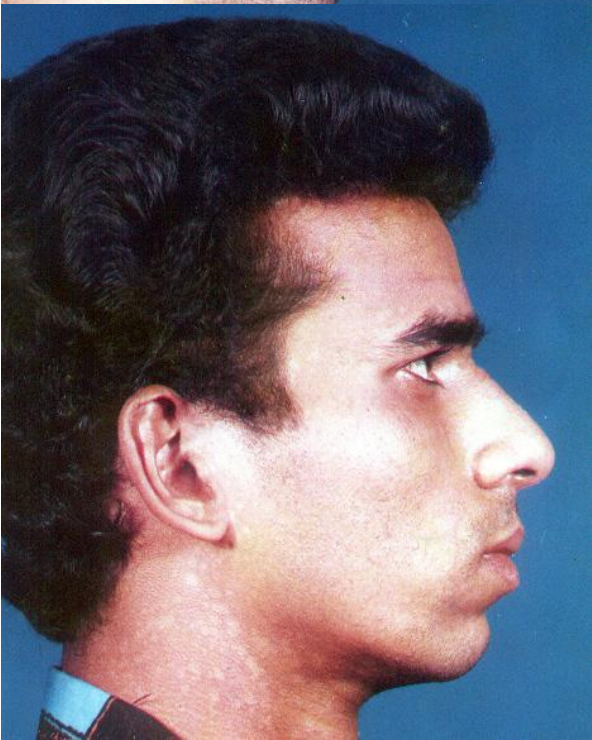
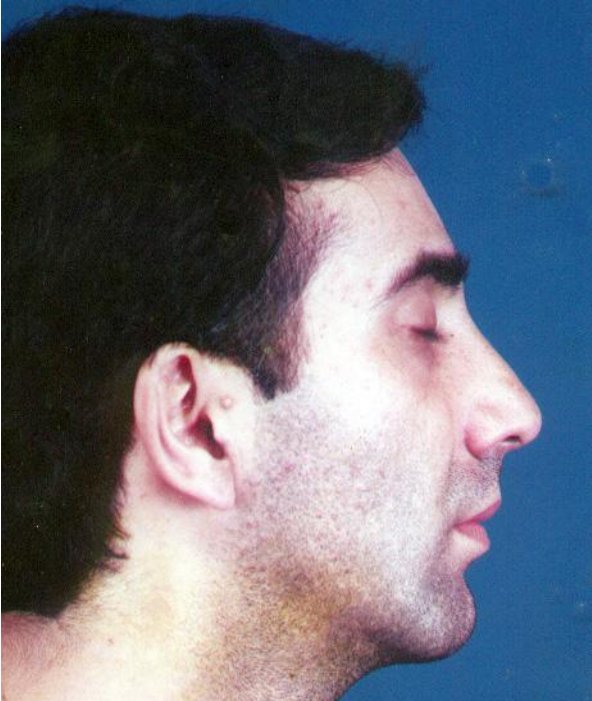


P
o
s
t
-
o
p

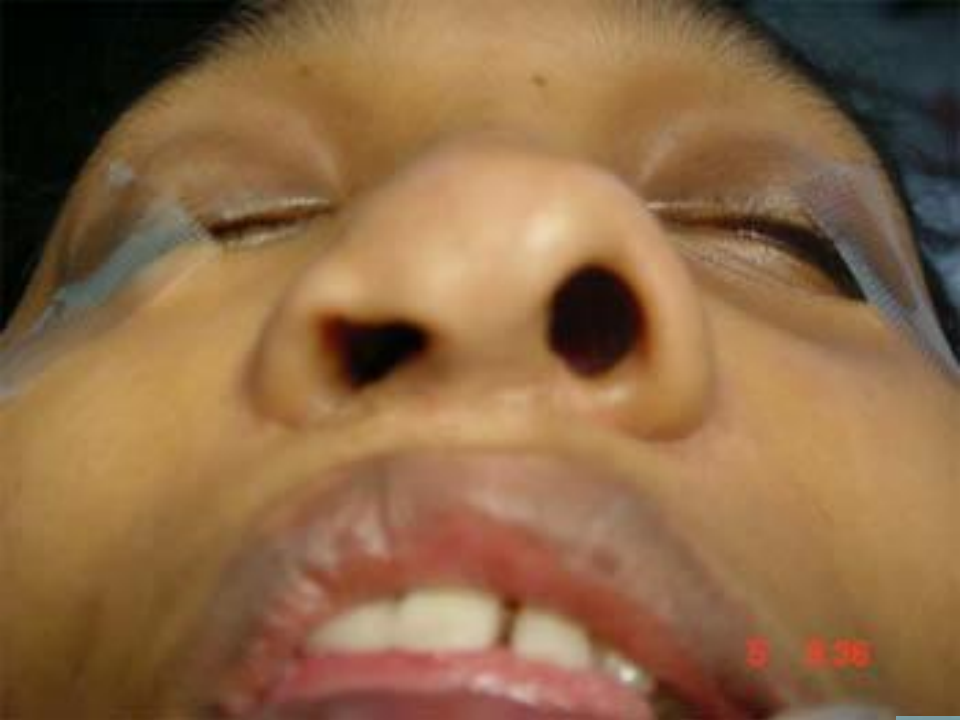
P
r
e
-
o
p



R
h
i
n
o
-
a
-
s
t
y

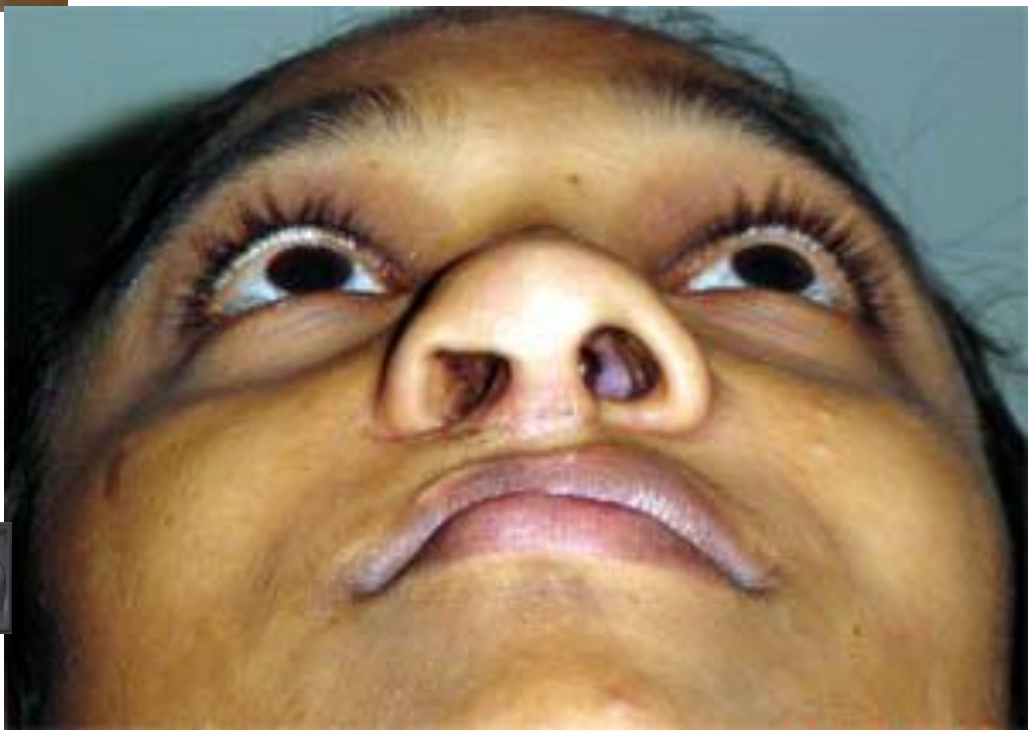

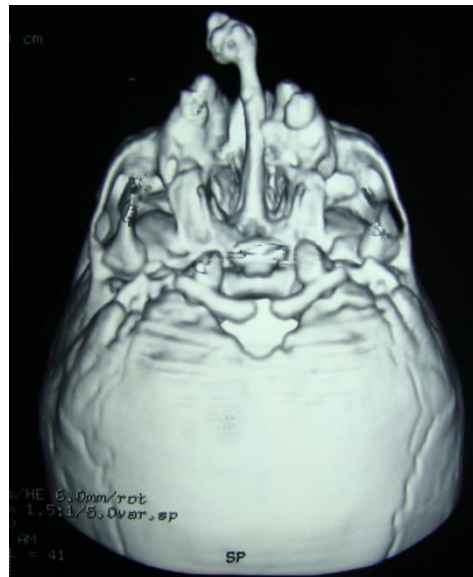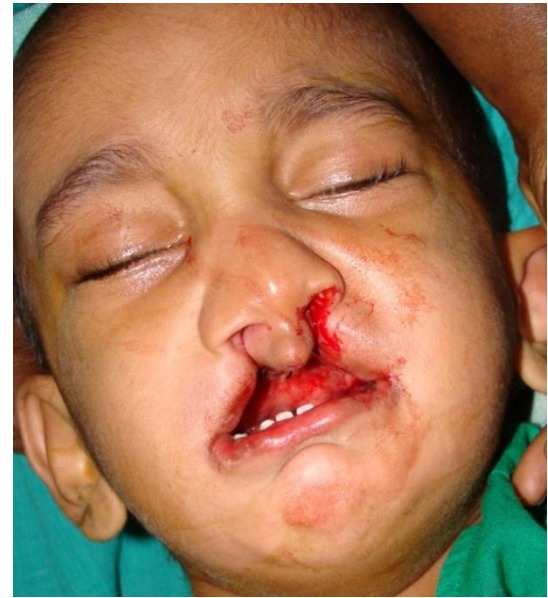
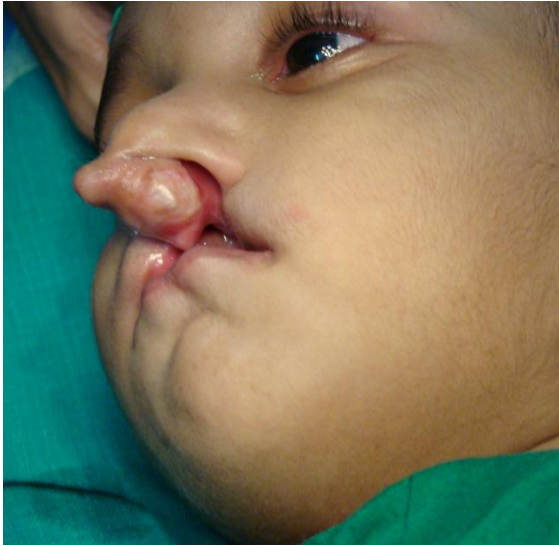P
o
s
t
-
o
p

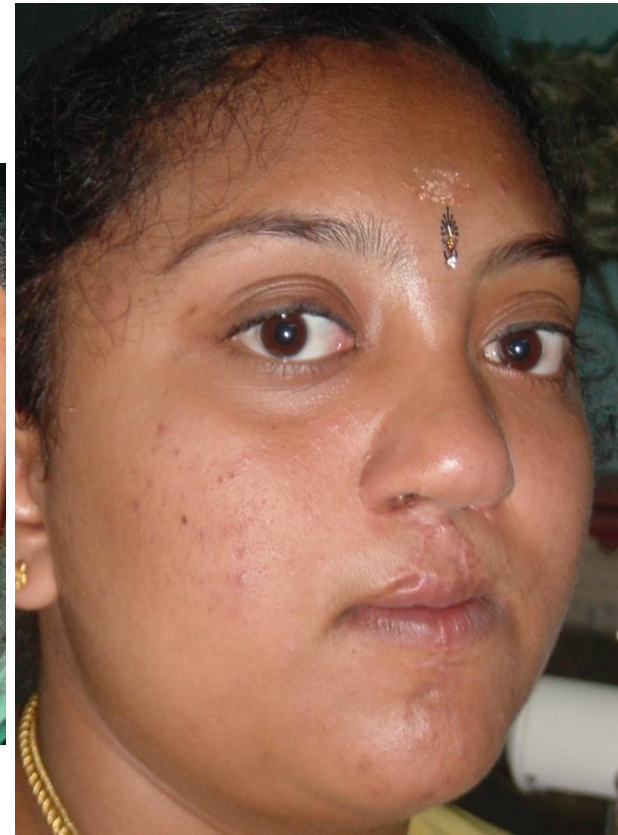
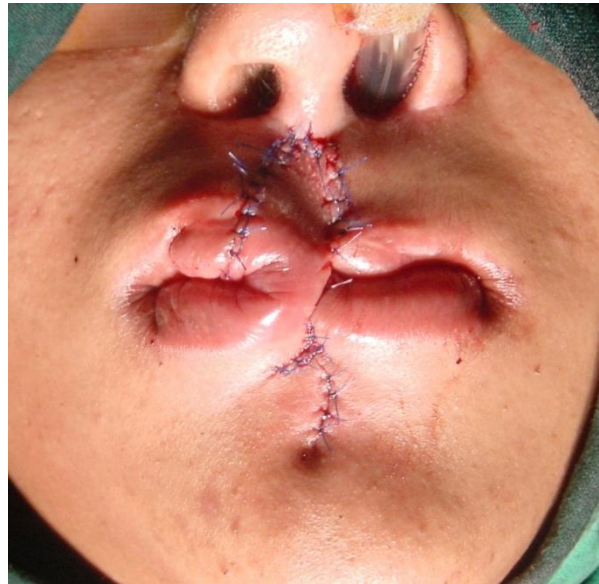

Preoperative

Postoperative







*As vertebrates climbed the ladder of evolution
Towards the goal of perfection
Brain enlarged for better cognition
Jaws lost many a function
Size suffered a gradual reduction
The seat of special sensory reception
Face moors the fine human expression
And aimed for the divine proportion*

